



Doctor's Copy

**PennHIP Report**

Referring Veterinarian: Dr Amanda Chrzanowski Email: lab@hahvet.com	Clinic Name: Heritage Animal Hospital (MI)  Clinic Address: 150 W Waterstradt Commerce Dr Dundee, MI 48131 Phone: (734) 529-9177 Fax: (734) 823-5337
--	---

**Patient Information**

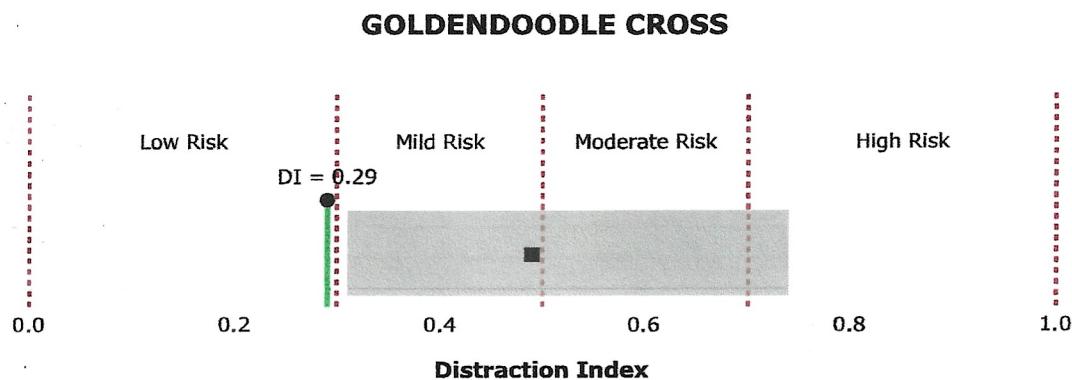
Client: KELLY, CAROLYN Patient Name: RUBY Reg. Name: PennHIP Num: 147121 Species: Canine Date of Birth: 15 Sep 2019 Sex: Female Date of Study: 22 Sep 2020 Date of Report: 23 Sep 2020	Tattoo Num: Patient ID: 373233RUB Registration Num: Microchip Num: Breed: GOLDENDOODLE CROSS Age: 12 months Weight: 54.6 lbs/24.8 kgs Date Submitted: 22 Sep 2020
--	--

**Findings**

Distraction Index (DI): Right DI = 0.28, Left DI = 0.29.  
Osteoarthritis (OA): **No radiographic evidence of OA for either hip.**  
Cavitation/Other Findings: No cavitation present.

**Interpretation**

Distraction Index (DI): The laxity ranking is based on the hip with the greater laxity (larger DI). In this case the DI used is 0.29.  
OA Risk Category: The DI is less than or equal to 0.30. This patient is at minimal risk for hip OA.  
Distraction Index Chart:



**BREED STATISTICS:** This interpretation is based on a cross-section of 2906 canine patients of the GOLDENDOODLE CROSS breed in the AIS PennHIP database. The gray strip represents the central 90% range of DIs (0.31 - 0.74) for the breed. The breed average DI is 0.49 (solid square). The patient DI is the solid circle (0.29).