



Owner's Copy

**PennHIP Report**

Referring Veterinarian: Dr Amanda Chrzanowski Email: lab@hahvet.com	Clinic Name: Heritage Animal Hospital (MI)  Clinic Address: 150 W Waterstradt Commerce Dr Dundee, MI 48131 Phone: (734) 529-9177 Fax:(734) 823-5337
--	---

**Patient Information**

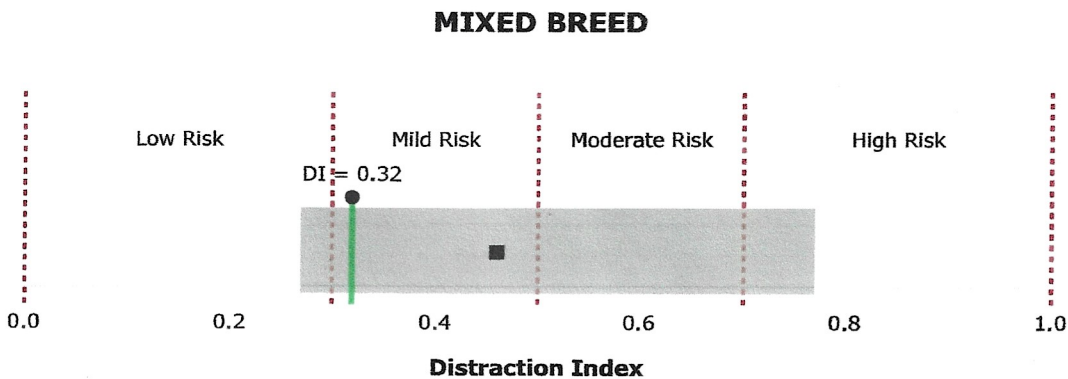
Client: KELLY, CAROLYN Patient Name: Rose Reg. Name: PennHIP Num: 179774 Species: Canine Date of Birth: 27 Sep 2021 Sex: Female Date of Study: 30 Sep 2022 Date of Report: 02 Oct 2022	Tattoo Num: Patient ID: 161420 Registration Num: Microchip Num: 985113005169925 Breed: MIXED BREED Age: 12 months Weight: 54.6 lbs/24.8 kgs Date Submitted: 30 Sep 2022
--	--

**Findings**

Distraction Index (DI): Right DI = 0.32, Left DI = 0.30. Osteoarthritis (OA): No radiographic evidence of OA for either hip. Cavitation/Other Findings: No cavitation present.
--

**Interpretation**

Distraction Index (DI): The laxity ranking is based on the hip with the greater laxity (larger DI). In this case the DI used is 0.32.  
OA Risk Category: The DI is between 0.31 and 0.49. This patient is at mild risk for hip OA.  
Distraction Index Chart:



**BREED STATISTICS:** This interpretation is based on a cross-section of 11813 canine patients of the MIXED BREED breed in the AIS PennHIP database. The gray strip represents the central 90% range of DIs (0.27 - 0.77) for the breed. The breed average DI is 0.46 (solid square). The patient DI is the solid circle (0.32).